

A diagnostic approach and natural course of a patient with asthma–COPD overlap syndrome

Hyun Lee¹, Nguyen Van Tho², Yasutaka Nakano³, Byung-Jae Lee⁴ & Hye Yun Park¹

¹Division of Pulmonary and Critical Care Medicine, Department of Medicine, Samsung Medical Center, Sungkyunkwan University School of Medicine, Seoul, Korea.

²Respiratory Care Center, University Medical Center, Ho Chi Minh City, Vietnam.

³Division of Respiratory Medicine, Department of Internal Medicine, Shiga University of Medical Science, Otsu, Shiga, Japan.

⁴Division of Allergy, Department of Medicine, Samsung Medical Center, Sungkyunkwan University School of Medicine, Seoul, South Korea.

Keywords

Asthma, chronic obstructive pulmonary disease, diagnosis.

Correspondence

Hye Yun Park, Division of Pulmonary and Critical Care Medicine, Department of Medicine, Samsung Medical Center, Sungkyunkwan University School of Medicine, 81 Irwon-ro, Gangnam-gu, Seoul 06351, Korea. E-mail: hyeyunpark@skku.edu

Received: 30 April 2015; Revised: 30 August 2015; Accepted: 01 September 2015.

Respirology Case Reports 2015; 3(4): 119–121

doi: 10.1002/rccr.12653

Abstract

The diagnostic criteria of asthma–chronic obstructive pulmonary disease (COPD) overlap syndrome (ACOS) advocated by the Global Initiative for Asthma (GINA)/Global Initiative for Chronic Obstructive Lung Disease (GOLD) are somewhat complicated, and limited data are available regarding how ACOS patients respond to current medications. We present a case of a 64-year-old man with ACOS. With features favoring asthma including childhood asthma history with intermittent episodes of dyspnea at night, elevated blood eosinophil count and total IgE, increased forced expiratory volume in 1 s (FEV₁) after bronchodilator (>200 mL and >12% from baseline), and positive skin prick tests, he also had features favoring COPD such as heavy smoker, persistent exertional dyspnea, and airflow limitation after inhaled therapy. Over 5-year follow up, our patient experienced a single episode of moderate exacerbation. However, post-bronchodilator FEV₁ decreased by 240 mL for 4 years (–60 mL/year) after 1.5 years of treatment, indicating rapid lung function decline. Longitudinal studies are necessary to assess optimal interventions and natural course of ACOS.

Introduction

Patients with clinical features of both asthma and chronic obstructive pulmonary disease (COPD) are commonly encountered in the clinical setting. Recently, there has been growing interest in identifying these patients in terms of asthma–COPD overlap syndrome (ACOS). A joint project of the Global Initiative for Asthma (GINA) and the Global Initiative for Chronic Obstructive Lung Disease (GOLD) provides a stepwise approach for diagnosing ACOS with check boxes for features that favor asthma or COPD [1].

Several studies suggested that patients with ACOS are more likely to have poorer outcomes, such as frequent exacerbations and low health-related quality of life, than patients with COPD alone [2, 3]. However, clinicians still face challenges in diagnosing ACOS in daily clinical practice because there are no definite diagnostic criteria for this disease. In addition, there are limited data regarding how ACOS patients respond to current medications. Thus, we herein present one patient who was diagnosed with ACOS and had the long-term follow up.

Case Report

A 64-year-old man presented with a 3-year history of exertional shortness of breath that had worsened over the past 3 months (modified Medical Research Council [mMRC] dyspnea grade of 3). He was a current smoker with a 60 pack-year history. He had a medical history of

This case report is an illustration of an invited review available in *Respirology*: <http://dx.doi.org/10.1111/resp.12653>. Tho NV; Park HY; and Nakano Y. Asthma–COPD Overlap Syndrome (ACOS): A Diagnostic Challenge. *Respirology*, 2015, doi:10.1111/resp.12653.

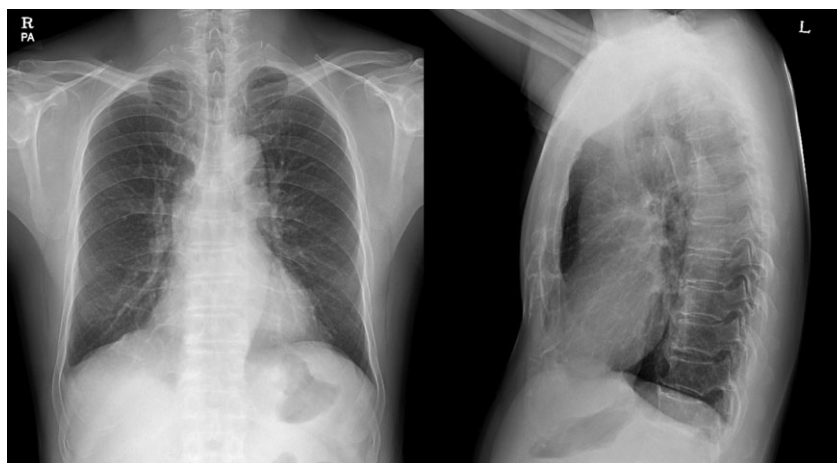

Figure 1. The posteroanterior and lateral chest X-rays show mild fattening of the diaphragms.

asthma since childhood. Over the previous 3 years, his cough, sputum, and dyspnea had worsened and he had experienced intermittent episodes of shortness of breath with wheezing at night. Whenever the symptoms developed, he would visit a nearby clinic where he was treated with oral prednisone and inhaled salbutamol. He was advised to undergo regular treatment including inhaled corticosteroids (ICS), but he did not follow his physician's advice.

On physical examination, the patient was alert and stable. His respiration rate was 18 breaths per minute, and his oxygen saturation in room air was 97%. His body mass index was 24 kg/m². Mild wheezes were heard during chest auscultation, and a chest X-ray showed mild diaphragm flattening (Fig. 1). Chest low-dose computed tomography, which was taken 1 year previously, showed no remarkable finding other than mild bronchiectasis in the right middle lobe. Pulmonary function tests showed an obstructive pattern with post-bronchodilator forced expiratory volume in 1 s (FEV₁)/forced vital capacity (FVC) of 59% and FEV₁ of 1.54 L (62% of predicted), with an increase in the FEV₁ of 210 mL and 16% from baseline values (Fig. 2). The pre- and post-bronchodilator FVC were 2.53 L (73% of predicted) and 2.61 L (75% of predicted), respectively. Laboratory findings revealed an elevated blood eosinophil count of 429/μL (6.6%) and elevated total IgE level of 1089 U/mL. He also had positive skin prick tests to three allergens: *Dermatophagoides pteronyssinus*, cockroach, and *Lepidoglyphus destructor*. The patient was diagnosed with asthma and possible COPD. He was advised to quit smoking and to use regular treatment including a combination of long-acting beta₂-agonist (LABA)/ICS plus slow-release theophylline. His subjective symptoms improved after 1 year of therapy, but he still had exertional dyspnea (mMRC dyspnea grade 2). The pre-bronchodilator FEV₁/

FVC, FEV₁, and FVC were 57%, 1.64 L (64% of predicted), and 2.87 L (80% of predicted), respectively. His inhaler technique was satisfactory and adherence to medication use was assessed to be good. At this time, he was diagnosed with ACOS because his airflow limitation and symptoms were persistent. A long-acting muscarinic antagonist (LAMA) was added to LABA/ICS. Despite the advice to quit smoking and offers regarding counseling or medication, he continued smoking half a pack per day. Two years later, he quit smoking with continuous education and the advice of his physician. He maintained regular therapy with LABA/ICS/LAMA and his post-bronchodilator FEV₁/FVC and FEV₁ when clinically stable were 56% and 1.52 L (63% of predicted) with an increase of 120 mL and 9% from baseline values. The pre- and post-bronchodilator FVC were 2.69 L (78% of predicted) and 2.71 L (79% of predicted), respectively. Five years and 6 months later, the post-bronchodilator FEV₁/FVC and FEV₁ when clinically stable were 48% and 1.37 L (57% of predicted) with an increase of 60 mL and 5% from baseline values (Fig. 2). The pre- and post-bronchodilator FVC were 2.65 L (76% of predicted) and 2.82 L (81% of predicted), respectively. There was a single moderate exacerbation requiring oral prednisone over 5 years.

Discussion

The present patient illustrates how ACOS can be applicable to a patient with a pre-existing diagnosis of asthma. The patient had clinical features favoring asthma such as a history of childhood asthma, worsening symptoms during the night, elevated blood eosinophil count and total IgE, increased FEV₁ after bronchodilator (>200 mL and >12% from baseline), and positive skin prick tests. The patient also had clinical features favoring COPD such as heavy

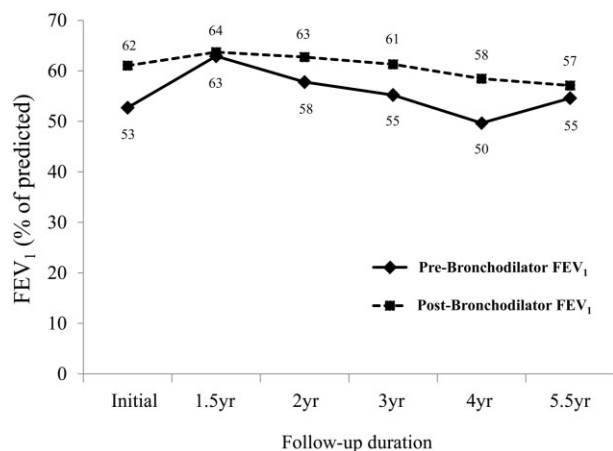


Figure 2. Change in pre- (dashed line) and post-bronchodilator (solid line) forced expiratory volume in 1 s (FEV₁) (% of predicted) over 5-year follow-up duration.

exposure to tobacco smoke, persistence of symptoms, and persistent airflow limitation after the inhaled therapy with LABA/ICS/LAMA.

As suggested in the ACOS review in *Respirology* [4], a definitive diagnosis of ACOS can often be postponed with follow-up monitoring. This is because most clinical features favoring asthma or COPD are based on the patient's history and present laboratory findings, but persistent airflow limitation, which is one of the clinical features favoring COPD, requires time to confirm. Thus, as shown in this case, when ACOS is suspected in patients with asthma and airflow limitation, a follow-up lung function test after regular inhaled therapy is necessary to confirm the presence of persistent airflow limitation.

In addition to pharmacological inhaled therapy, it is important to identify and eliminate modifiable risk factors. In particular, smoking is associated with an accelerated decline in lung function, increased mortality, worsening symptoms, and a poor response to ICS in both asthma and COPD. Although smokers understand the benefits of smoking cessation, many of them continue to smoke, as in the present case. Thus, repeated education and smoking cessation support provided by health professionals need to be strongly emphasized.

Regarding the natural course of COPD, Asian patients with COPD in the UPLIFT trial showed a trend toward a

reduced annual rate of decline in the post-bronchodilator FEV₁ (−26 mL/year in the tiotropium group) relative to patients in other regions of the world [5]. The presented patient did not develop frequent exacerbations, but there was 240 mL reduction in post-bronchodilator FEV₁ over 4 years (−60 mL/year) after 1.5 year of treatment, suggesting a rapid decline in lung function compared with annual rate of decline in Asian COPD patients. This rapid rate of decline in FEV₁ might be due to the combination of asthma and smoking [6]. Prospective longitudinal studies are necessary to assess the natural course of ACOS with optimal interventions.

Disclosure Statements

YN received honoraria for speaking at meetings from Nippon Boehringer Ingelheim Co., Ltd., and GlaxoSmithKline K.K. He has been reimbursed by Olympus Corporation for being on an advisory board. Appropriate written informed consent was obtained for publication of this case report and accompanying images.

References

- GINA and GOLD. 2015. GINA and GOLD: diagnosis of diseases of chronic airflow limitation: asthma, COPD and asthma-COPD overlap syndrome (ACOS). Available at: http://www.ginasthma.org/local/uploads/files/ACOS_2015.pdf (accessed 19 January 2015).
- Miravittles M, Soriano JB, Ancochea J, et al. 2013. Characterisation of the overlap COPD-asthma phenotype. Focus on physical activity and health status. *Respir. Med.* 107:1053–1060.
- Hardin M, Cho M, McDonald ML, et al. 2014. The clinical and genetic features of COPD-asthma overlap syndrome. *Eur. Respir. J.* 44:341–350.
- Tho NV, Park HY, and Nakano Y. 2015. Asthma-COPD Overlap Syndrome (ACOS): a diagnostic challenge. *Respirology*.
- Fukuchi Y, Fernandez L, Kuo HP, et al. 2011. Efficacy of tiotropium in COPD patients from Asia: a subgroup analysis from the UPLIFT trial. *Respirology* 16:825–835.
- James AL, Palmer LJ, Kicic E, et al. 2005. Decline in lung function in the Busselton Health Study: the effects of asthma and cigarette smoking. *Am. J. Respir. Crit. Care Med.* 171:109–114.