

## An alcoholic patient with pneumonia induced by multiple pathogens simultaneously: To use corticosteroid or not?

Ho Lam Nguyen\* ; Thuong Vu Le; Van Ngoc Tran

\*Ho Lam Nguyen

Department of Internal Medicine, University of Medicine and Pharmacy - Ho Chi Minh city, VietNam  
Email: bsholam1986@gmail.com

### Abstract

A 42-year-old male patient with history of alcohol abuse presented at a district hospital with fever and right chest pain. With diagnosis of severe pneumonia, he was treated with broad-spectrum antibiotics for seven days, but his clinical status was instable. Therefore, he was transferred to a tertiary hospital. Here several differential diagnoses were investigated aggressively and systemically. The results of bronchoalveolar lavage (BAL) fluid cultures showed the presence of multiple pathogens, including Extended-spectrum-Beta-lactamase (ESBL) producing *Klebsiella pneumoniae*, multidrug-resistant (MDR) *Pseudomonas aeruginosa*, and *Candida albicans*. The appropriate antibiotics and antifungal agent were initiated coupled with the adjunctive corticosteroid therapy. Although this regimen for the alcoholic patient with multiple-pathogen-induced pneumonia has never been reported, we were successful with patient recovered uneventfully. We concluded that a nonresponding pneumonia in alcoholic patient could be caused by multiple pathogens, especially in patients with a prolonged hospital stay and the corticosteroid should be considered using in similar cases.

### Keywords

alcohol abuse and pneumonia; candidiasis; corticosteroids and pneumonia; nonresponding pneumonia; polymicrobial pneumonia

### Introduction

Nonresponding pneumonia is estimated up to 6-15% of hospitalized patients with community-acquired pneumonia (CAP) and increased to 40% of severe CAP patients requiring intensive care unit admission [1]. Nonresponding pneumonia is common in alcoholic patients [2] because of some reasons such as (1) alcohol abuse affecting adversely the systemic immune and the defense mechanism of the lung [3], (2) pneumonia improved slowly relating to malnutrition in alcoholic patients, and (3) the risk of nosocomial superinfection with a prolonged hospital stay. Therefore, this condition in alcoholic patient is really a challenge for clinicians.

The role of corticosteroid in CAP patients has been published recently [4-7]. However, the use of corticosteroid in alcoholic patient diagnosed with pneumonia has never been reported before. Here we reported a case of successful treatment of an alcoholic patient, who was diagnosed with nonresponding pneumonia induced by multiple pathogens, using corticosteroid.

## Case Presentation

A 42-year-old male patient hospitalized at a district hospital with fever and right pleuritic pain three days ago. He coughed up blood-streaked sputum and felt breathlessness, fatigue, and anorexia. On average, he had drunk half a liter of alcohol per day since 2005. He had been diagnosed with severe CAP and septic shock and treated with meropenem and levofloxacin for seven days, but he still had fever. He was transferred to a tertiary hospital with diagnosis of nonresponding pneumonia. Here on clinical examination, he was alert, body mass index 17.7 kg/m<sup>2</sup>, pulse rate 130/min, blood pressure 160/90 mmHg, temperature 39°C, respiratory rate 28/min, and peripheral capillary oxygen saturation 90% with 3 L/min oxygen via nasal cannula. The right lower lung field examination revealed decreased tactile fremitus, dull on percussion, decreased breath sounds and coarse crackles.

The cell blood count showed hematocrit 24.4% and white blood cells 16.2 K/mm<sup>3</sup> with Neutrophils 83.1%. The level of serum C-reactive protein was 113.1 mg/L. Liver function test, serum urea and creatinine levels, and serum electrolyte were in normal range. An arterial blood gas analysis revealed pH 7.57, PaO<sub>2</sub> 56.2 mmHg, PaCO<sub>2</sub> 29.5 mmHg, and HCO<sub>3</sub><sup>-</sup> 27.2 mmol/L. We discussed his family to perform the rapid HIV antibody test and its result was negative. The chest radiograph on admission into tertiary hospital showed ill-defined opacities in the right lower hemithorax (Fig. 1). The chest computerized tomography with contrast material was also done and revealed the right lower lobe consolidation and pleural effusion (Fig. 2).

We diagnosed a severe CAP not responding to initiation of antimicrobial therapy and parapneumonic effusion. Piperacillin/tazobactam, amikacin, vancomycin, and metronidazole were used to cover both aerobic gram-negative and gram-positive bacteria and anaerobic bacteria.

On admission into tertiary hospital, the Tuberculosis (TB) tests such as acid-fast bacilli (AFB) testing in both sputum and pleural fluid, polymerase chain reaction with pleural fluid, and adenosine deaminase in pleural fluid were negative. We collected samples for bacterial cultures such as blood, pleural fluid, and sputum and these results of cultures showed no pathogen discovered. We therefore decided to stop using vancomycin. Although cytological analysis of pleural fluid appeared with Neutrophils 42%, there is no any feature of complicated parapneumonic effusion. On the fifth hospital day he still had fever, fatigue and diarrhea with 4-6 times per day.

Consequently, we repeated the tests to look for pathogens, as follows: bacterial blood culture, fungal blood culture, pleural fluid culture with the second thoracentesis, but all these tests answered again no pathogen seen. We also conducted fecal smear microscopy and culture which revealed leukocytes and yeasts. The second thoracentesis showed the prominent lymphocyte in cytological analysis 80%. Therefore, a diagnosis of empyema was excluded. Blind transthoracic lung biopsy showed fibroblastic proliferation, infiltration of lymphocytes and histiocytes, and edematous stroma (Fig. 3). Flexible bronchoscopy showed yellow mucus plug at segmental bronchi of the right inferior lobe (Fig. 4) and we collected BAL fluid to perform AFB testing, bacterial culture, and fungal culture. No AFB was seen on BAL fluid smear microscopy. The results of BAL fluid cultures found out multiple pathogens as follows: ESBL producing *Klebsiella pneumoniae*, MDR *Pseudomonas aeruginosa*, and *Candida albicans*.

So, we treated the patient with appropriate combination of antimicrobial and antifungal drugs

which included meropenem, colistin, and amphotericin B. However, there was no clinical improvement on the fourth day of this drug combination – he still had mild fever, fatigue and his respiratory failure unchanged. At this time, the systemic corticosteroid was added because of the aforementioned histopathology of lung biopsy and the appearance of pruritic erythematous papules on his skin (Intravenous methylprednisolone 40 microgram per day). After treatment with the adjunctive corticosteroid four days, the patient's symptoms were improved. He was discharged on the eighth day of using antibiotics and antifungal agent coupled with corticosteroid uneventfully. Follow up one month later, the healthy patient returned outpatient clinic and the chest radiograph showed the lesion at the right lower lung disappeared completely (Fig. 5).

## Discussion

Many interacting factors result in a failure to respond to antibiotic treatment in patient with pneumonia. We used a chart of “disease triangle” to analyze this case of nonresponding pneumonia. Successful management of pneumonia requires resolving all three factors of disease triangle which includes host susceptibility, pathogenicity, and environment [8]. In this case, the host susceptibility implied the patient's characteristics such as malnutrition, the past history of alcohol abuse, the differential diagnoses of fever (HIV, Mycobacterium Tuberculosis, lung tumor), and the complications of pneumonia (sepsis, complicated parapneumonic effusion, and empyema). The investigation of pathogenicity (pathogens relating to nosocomial superinfection) and environment (antimicrobial and antifungal drugs) were two key factors contributing to treat successfully. Here we notice that nonresponding pneumonia was induced by multiple pathogens such as ESBL producing *Klebsiella pneumoniae*, MDR *Pseudomonas aeruginosa*, and *Candida albicans*. We used the combination of antimicrobial and antifungal drugs (Meropenem, Colistin, and Amphotericin B) according to the results of antibiotic and antifungal susceptibility testing.

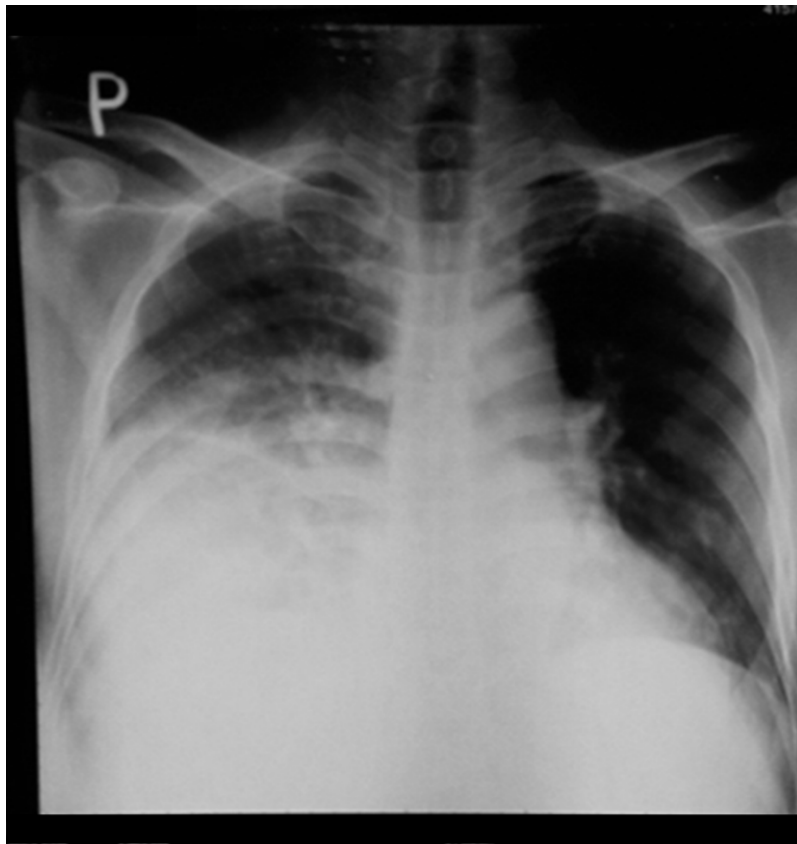
The adjunctive corticosteroids therapy seemed contributing in the improvement of clinical outcome of pneumonia. Several published clinical trials concluded the potential effect of adjunctive corticosteroids therapy in patients with severe CAP[4-6], especially in severe CAP patients with high associated inflammatory response [7]. The CAP severity in this case was FINE-IV (FINE scale) and the serum CRP of inflammatory response was 113.2 mg/L. The pathological examination of lung biopsy appeared features compatible with organizing pneumonia (an organizing pneumonia of determined cause). The corticosteroid treatment can be helpful to organize pneumonia. Therefore, we think that the corticosteroid treatment in this case was necessary.

We also have some limitations in this case. The first, the test to look for atypical bacteria had never been performed. For instance, *Legionella* can be one of the common pathogens of severe CAP, the nosocomial superinfection with a prolonged hospital stay, and particularly co-infection in severe pneumonia with *Pseudomonas aeruginosa* [9]. The second, diagnosis of fungal pneumonia (pulmonary candidiasis) was uncertain. This patient was several risk factors of invasive candidiasis -Long term treatment with broad-spectrum antibiotics, *Candida albicans* appearing on the result of BAL fluid culture and a fecal smear microscopy showing yeasts, but the result of fungal blood culture was negative. However, in our opinion, initiation of antifungal therapy in this case was necessary. The final clinical outcome in this case strongly supports making a decision of this treatment.

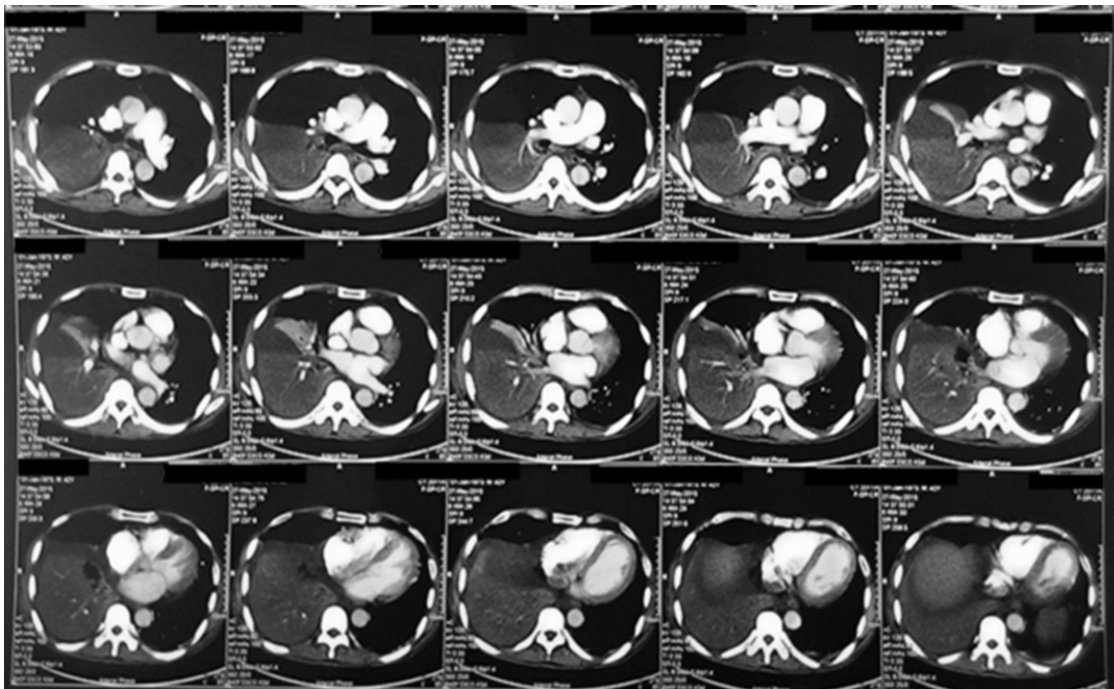
## Acknowledgments

We thank Mrs. Thanh Thu Tran Thi who assisted to edit the English of this manuscript.

## Figures

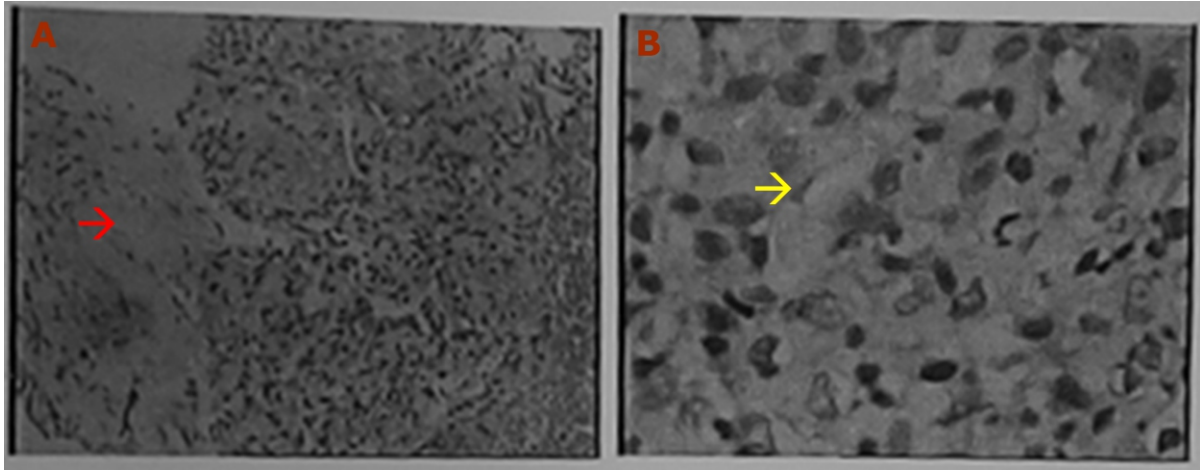


**Figure 1:** Chest radiograph on admission at a tertiary hospital. It revealed heterogeneous opacities in the right lower lung and blunting right costophrenic angle.

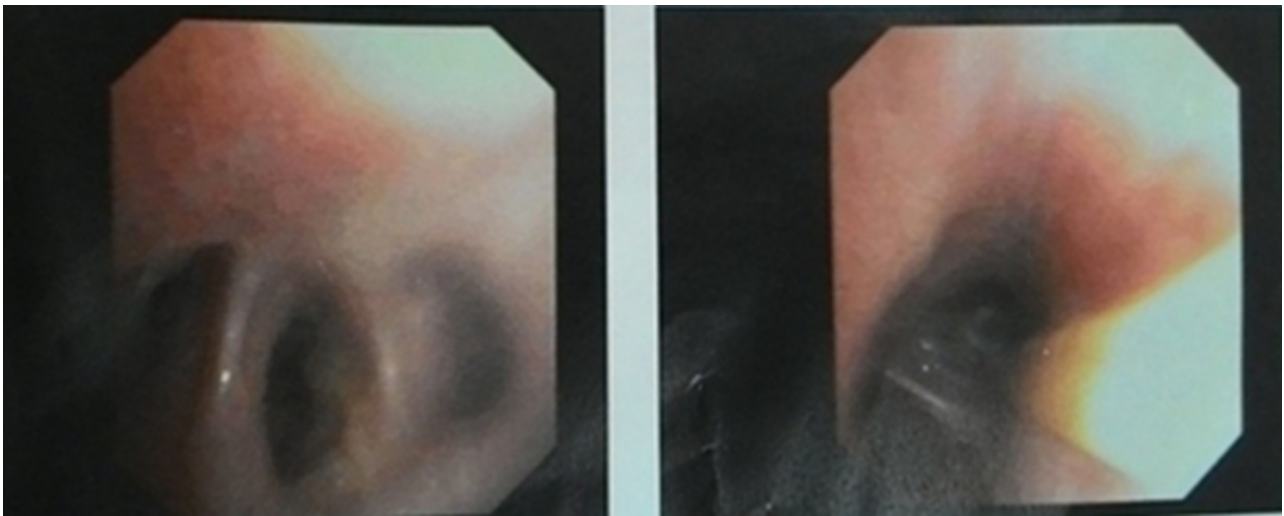


**Figure 2:** Chest computerized tomography with contrast material. It showed a consolidation in the right lower lobe and pleural effusion.

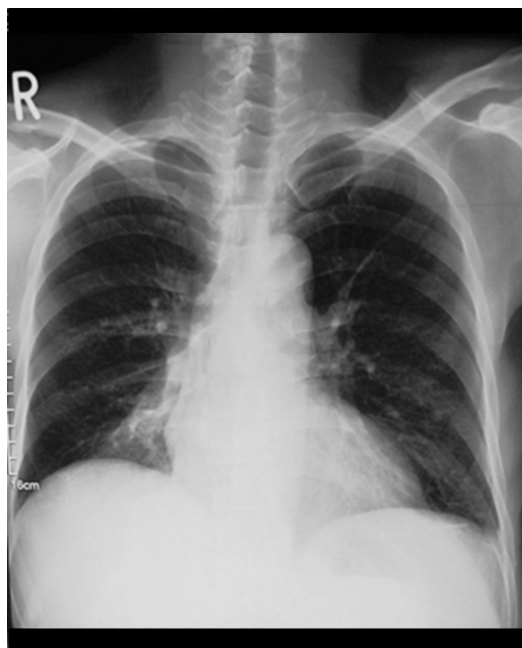




**Figure 3:** Pathological examination of lung specimen showed the edematous stroma (red arrow, Image A 100X magnification), the proliferation of fibroblasts (yellow arrow, Image B 400X magnification), and the infiltration of lymphocytes and histiocytes. These features were compatible with organizing pneumonia.



**Figure 4:** Bronchoscopy showed yellow mucus plug at segmental bronchi of the right lower lobe.



**Figure 5:** Chest radiograph on follow up one month after discharged. The lesion in the right lower lung disappeared almost completely.

## References

1. Mandell LA, Wunderink RG, Anzueto A, Bartlett JG, Campbell GD, Dean NC, et al. Infectious Diseases Society of America/American Thoracic Society consensus guidelines on the management of community-acquired pneumonia in adults. *Clin Infect Dis*. 2007;44:S27-72. Epub 2007/02/06.
2. Finch S, Chalmers JD. Brief clinical review: Non-responding pneumonia. *EMJ Respir*. 2014;2:104-11.
3. Boé DM, Vandivier RW, Burnham EL, Moss M. Alcohol abuse and pulmonary disease. *J Leukoc Biol*. 2009;86:1097-104.
4. Marti C, Grosgrain O, Harbarth S, Combescure C, Abbas M, Rutschmann O, et al. Adjunctive Corticotherapy for Community-Acquired Pneumonia: A Systematic Review and Meta-Analysis. *PLOS ONE*. 2015.
5. Salluh JI, Póvoa P, Soares M, Castro-Faria-Neto HC, Bozza FA, Bozza PT. The role of corticosteroids in severe community-acquired pneumonia: a systematic review. *Crit Care*. 2008;12(3):R76.
6. Siemieniuk RAC, Meade MO, Alonso-Coello P, Briel M, Evaniew N, Prasad M, et al. Corticosteroid Therapy for Patients Hospitalized With Community-Acquired Pneumonia: A Systematic Review and Meta-analysis. *Ann Intern Med*. 2015. Epub 2015/08/11.
7. Torres A, Sibila O, Ferrer M, Polverino E, Menendez R, Mensa J, et al. Effect of corticosteroids on treatment failure among hospitalized patients with severe community-acquired pneumonia and high inflammatory response: a randomized clinical trial. *JAMA*. 2015;313:877-86.
8. van-Baarlen P, van-Belkum A, Summerbell RC, Crous PW, Thomma BPHJ. Molecular mechanisms of pathogenicity: how do pathogenic microorganisms develop cross-kingdom host jumps? *FEMS Microbiol Rev*. 2007;31:239-77.
9. Roig J, Rello J, Yu VL. Legionnaires' disease: a rational approach to therapy. *J Antimicrob Chemother*. 2003;51:1119-29.

**Manuscript Information:** Received: November 05, 2016; Accepted: February 01, 2017; Published: February 03, 2017

**Authors Information:** Ho Lam Nguyen\* ; Thuong Vu Le; Van Ngoc Tran

Department of Internal Medicine, University of Medicine and Pharmacy - Ho Chi Minh city, VietNam

**Citation:** Nguyen HL, Le TV, Tran VN. An alcoholic patient with pneumonia induced by multiple pathogens simultaneously: To use corticosteroid or not? *Open J Clin Med Case Rep*. 2017; 1217

**Copy right statement:** Content published in the journal follows Creative Commons Attribution License (<http://creativecommons.org/licenses/by/4.0>). © **Nguyen HL**

**Journal:** Open Journal of Clinical and Medical Case Reports is an international, open access, peer reviewed Journal focusing exclusively on case reports covering all areas of clinical & medical sciences.

Visit the journal website at [www.jclinmedcasereports.com](http://www.jclinmedcasereports.com)

For reprints & other information, contact editorial office at [info@jclinmedcasereports.com](mailto:info@jclinmedcasereports.com)